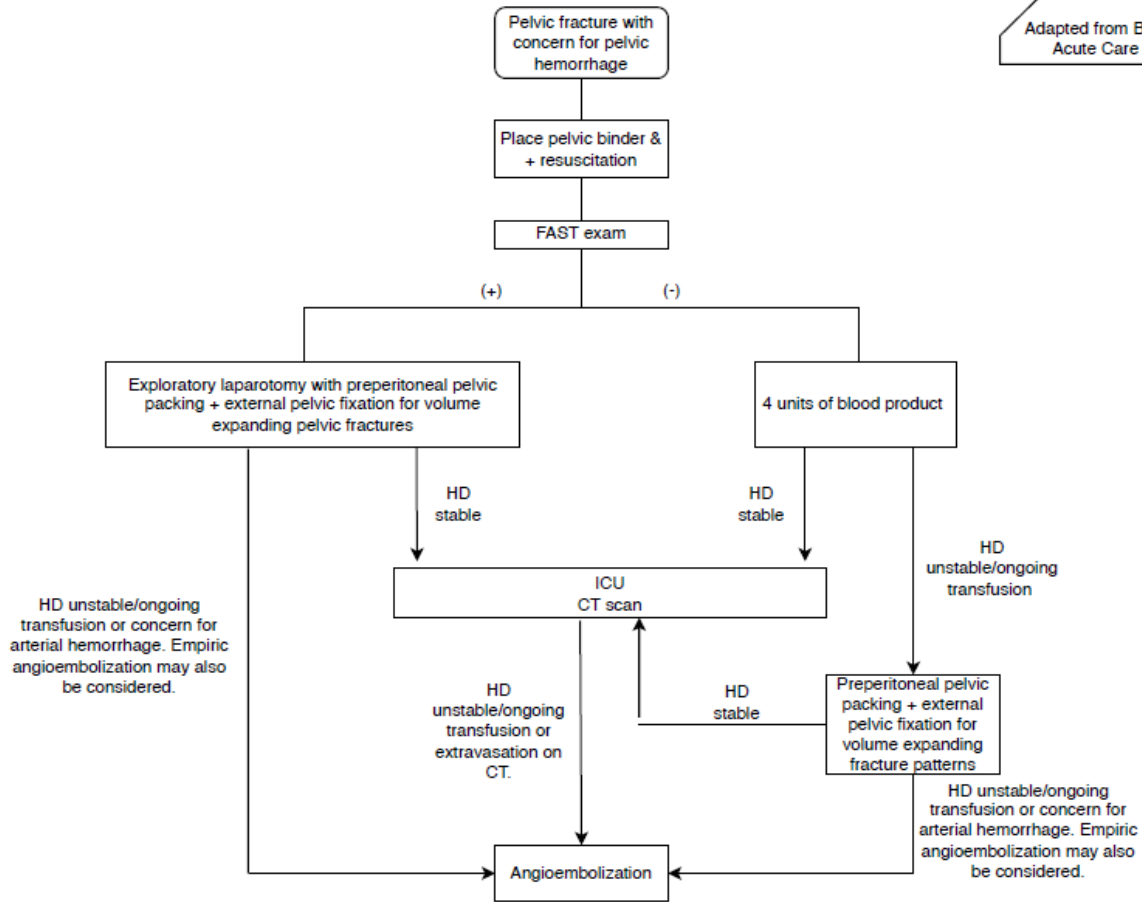


Adapted from Burlew et al, J Trauma Acute Care Surg. 2017; 82(2)



- Subclavian central line is preferred over femoral
- In eligible patients, whole blood is preferred over component therapy
- Zone III REBOA can be considered in patients with hard to control hemorrhage
- When performed with exploratory laparotomy, preperitoneal pelvic packing should be completed through a separate incision (lower midline or Pfannenstiel)
- Except in circumstances where it will lead to delay in hemorrhage control, external pelvic fixation should be performed BEFORE preperitoneal packing
- Packs should be removed within 24 hours of placement
- When booking the OR, ask for orthopedic pelvic fixation set (large ex fix tray, 250mm Shantz pins, curved pelvic bars, system 7 or 8 drill), large c-arm fluoroscopy, and radiolucent flat top OR table
- Pelvic ring fractures with significant displacement require evaluation for possible rectal injury with proctoscopy, vaginal injury with speculum exam, urethral injury with urethrogram, and bladder injury with cystogram.

Parent Policy: InsertLinkToParentPolicy	Title: Pelvic Fracture Guideline- WMR	Standard Operating Procedure Effective Date: 10/21/2022
--------------------------------------------	------------------------------------------	------------------------------------------------------------

References

- Li P, Liu F, Li Q, Zhou D, Dong J, Wang D. Role of pelvic packing in the first attention given to hemodynamically unstable pelvic fracture patients: a meta-analysis. *J Orthop Traumatol*. 2022 Jul 7;23(1):29. doi: 10.1186/s10195-022-00647-6. PMID: 35799073; PMCID: PMC9263021.
- McDonogh JM, Lewis DP, Tarrant SM, Balogh ZJ. Preperitoneal packing versus angioembolization for the initial management of hemodynamically unstable pelvic fracture: A systematic review and meta-analysis. *J Trauma Acute Care Surg*. 2022 May 1;92(5):931-939. doi: 10.1097/TA.0000000000003528. Epub 2022 Jan 5. PMID: 34991126; PMCID: PMC9038232.
- Coccolini F, Stahel PF, Montori G, Biffi W, Horer TM, Catena F, Kluger Y, Moore EE, Peitzman AB, Ivatury R, Coimbra R, Fraga GP, Pereira B, Rizoli S, Kirkpatrick A, Leppaniemi A, Manfredi R, Magnone S, Chiara O, Solaini L, Ceresoli M, Allievi N, Arvieux C, Velmahos G, Balogh Z, Naidoo N, Weber D, Abu-Zidan F, Sartelli M, Ansaloni L. Pelvic trauma: WSES classification and guidelines. *World J Emerg Surg*. 2017 Jan 18;12:5. doi: 10.1186/s13017-017-0117-6. PMID: 28115984; PMCID: PMC5241998.
- Burlew CC, Moore EE, Stahel PF, Geddes AE, Wagenaar AE, Pieracci FM, Fox CJ, Campion EM, Johnson JL, Mauffrey C. Preperitoneal pelvic packing reduces mortality in patients with life-threatening hemorrhage due to unstable pelvic fractures. *J Trauma Acute Care Surg*. 2017 Feb;82(2):233-242. doi: 10.1097/TA.0000000000001324. PMID: 27893645; PMCID: PMC5250563.
- Burlew CC, Moore EE, Smith WR, Johnson JL, Biffi WL, Barnett CC, Stahel PF. Preperitoneal pelvic packing/external fixation with secondary angioembolization: optimal care for life-threatening hemorrhage from unstable pelvic fractures. *J Am Coll Surg*. 2011 Apr;212(4):628-35; discussion 635-7. doi: 10.1016/j.jamcollsurg.2010.12.020. PMID: 21463801.
- Cullinane DC, Schiller HJ, Zielinski MD, Bilaniuk JW, Collier BR, Como J, Holevar M, Sabater EA, Sems SA, Vassy WM, Wynne JL. Eastern Association for the Surgery of Trauma practice management guidelines for hemorrhage in pelvic fracture--update and systematic review. *J Trauma*. 2011 Dec;71(6):1850-68. doi: 10.1097/TA.0b013e31823dca9a. PMID: 22182895.
- Lustenberger T, Störmann P, Eichler K, Nau C, Janko M, Marzi I. Secondary Angio-Embolization After Emergent Pelvic Stabilization and Pelvic Packing Is a Safe Option for Patients With Persistent Hemorrhage From Unstable Pelvic Ring Injuries. *Front Surg*. 2020 Dec 17;7:601140. doi: 10.3389/fsurg.2020.601140. PMID: 33392246; PMCID: PMC7773821.
- Li Q, Dong J, Yang Y, Wang G, Wang Y, Liu P, Robinson Y, Zhou D. Retroperitoneal packing or angioembolization for haemorrhage control of pelvic fractures--Quasi-randomized clinical trial of 56 haemodynamically unstable patients with Injury Severity Score \geq 33. *Injury*. 2016 Feb;47(2):395-401. doi: 10.1016/j.injury.2015.10.008. Epub 2015 Oct 22. PMID: 26508436.
- Tesoriero RB, Bruns BR, Narayan M, Dubose J, Guliani SS, Brenner ML, Boswell S, Stein DM, Scalea TM. Angiographic embolization for hemorrhage following pelvic fracture: Is it "time" for a paradigm shift? *J Trauma Acute Care Surg*. 2017 Jan;82(1):18-26. doi: 10.1097/TA.0000000000001259. PMID: 27602911.
- Schwartz DA, Medina M, Cotton BA, Rahbar E, Wade CE, Cohen AM, Beeler AM, Burgess AR, Holcomb JB. Are we delivering two standards of care for pelvic trauma? Availability of angioembolization after hours and on weekends increases time to therapeutic intervention. *J Trauma Acute Care Surg*. 2014 Jan;76(1):134-9. doi: 10.1097/TA.0b013e3182ab0cfc. PMID: 24368368.
- Yoshihara H, Yoneoka D. Demographic epidemiology of unstable pelvic fracture in the United States from 2000 to 2009: trends and in-hospital mortality. *J Trauma Acute Care Surg*. 2014 Feb;76(2):380-5. doi: 10.1097/TA.0b013e3182ab0cde. PMID: 24398776.
- Vaidya R, Scott AN, Tonnos F, Hudson I, Martin AJ, Sethi A. Patients with pelvic fractures from blunt trauma. What is the cause of mortality and when? *Am J Surg*. 2016 Mar;211(3):495-500. doi: 10.1016/j.amjsurg.2015.08.038. Epub 2015 Dec 31. PMID: 26781723.