

# Evolution of the Surgical Management of Neonatal Ovarian Cysts: Laparoscopic-Assisted Transumbilical Extracorporeal Ovarian Cystectomy (LATEC)\*

Lucy Schenkman, BA, Timothy M. Weiner, MD, and J. Duncan Phillips, MD

## Abstract

**Purpose:** Since its first detailed description in 1995, the laparoscopic management of neonatal ovarian cysts has typically required multiple incisions, specialized equipment, and advanced laparoscopic skills. After some initial frustration with neonatal laparoscopy, we developed a simplified single-incision laparoscopic-assisted transumbilical extracorporeal cystectomy (LATEC). This paper reviews our experience with this technique and compares outcomes to those of our other surgically managed neonatal ovarian cyst patients.

**Materials and Methods:** A retrospective record review of 20 patients treated surgically between 1992 and 2006. Student's *t*-tests were used for comparisons ( $P < 0.05$  was significant).

**Results:** Means were: age, 11 days; weight, 3.7 kg; and cyst diameter, 5.0 cm. Nineteen patients were diagnosed prenatally, at the mean gestational age of 33 weeks. Twelve of 20 (60%) had torsed cysts (1 bilateral). Three of 13 torsed cysts (23%) were less than 4 cm diameter (range, 2.9–3.5). Laparotomies were transverse lower abdominal incisions. Laparoscopic operations used 2 (3 patients) or 3 incisions (2 patients). LATEC involved transumbilical laparoscopy, complete cyst aspiration, and then cyst evisceration through the umbilicus for either ovarian cystectomy (simple cysts) or salpingo-oophorectomy (torsed cysts). Laparoscopic patients had similar time to feeds, length of stay, and postoperative narcotic requirements, when compared to laparotomy patients ( $P =$  nonsignificant). LATEC patients had shorter surgical times, more rapid advancement to full enteral feedings, shorter length of hospital stay, and equal ovarian preservation, when compared to laparoscopy. Cosmetic results with LATEC were outstanding.

**Conclusions:** Both laparoscopic and "open" approaches have acceptable perioperative morbidity and rapid recovery. LATEC is a relatively simple procedure, which combines laparoscopy and traditional extracorporeal surgery, and may be successfully performed by experienced pediatric surgeons and with a single incision.

## Introduction

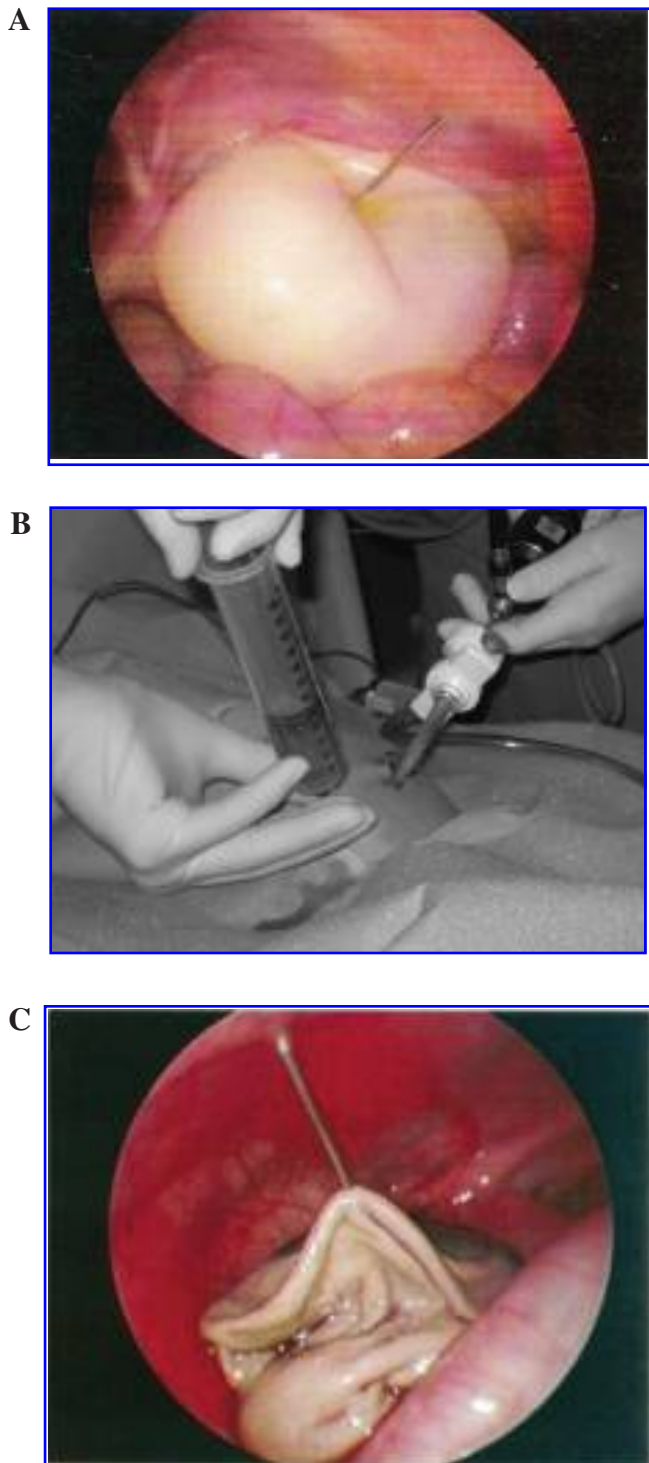
ANTENATAL ULTRASOUND DETECTION of a fetal ovarian cyst was first reported in 1975.<sup>1</sup> With the increasing utilization of routine prenatal ultrasound, the number of cysts detected (and reported) has risen dramatically.<sup>2</sup> A 1991 review of this topic revealed 257 reported cases of antenatally diagnosed ovarian cysts.<sup>3</sup> In general, simple cysts of less than 4–5 cm in diameter tend to resolve spontaneously within the first 4–5 months of postnatal life and, therefore, typically do not require surgical treatment. Surgery has been recommended for simple cysts greater than 4 cm in diameter, which have a high rate of future ovarian torsion and necrosis, and for complex cysts, which often have already undergone torsion.<sup>3,4</sup> Neonatal ovarian

torsion and infarction can lead to adhesions to the bowel and complications, which include intestinal obstruction<sup>5–8</sup> compression of the urinary tract, compression of the vena cava, cyst rupture,<sup>9</sup> and bilateral ovarian loss.<sup>10</sup> Complex cysts may be distinguished on ultrasound by: a fluid-debris ("fluid-fluid") level, a cystic appearance with a retracting clot, septations with or without internal echoes, or by a solid appearance.<sup>2</sup>

Initial approaches to the resection of neonatal ovarian cysts involved laparotomy. Recent modifications of the "open" technique have been reported.<sup>11</sup> Laparoscopic removal of a neonatal ovarian cyst was first described in detail in 1995.<sup>4</sup> Both laparotomy<sup>11</sup> and laparoscopy<sup>4,12</sup> have been shown, individually, to be safe and effective in the surgical management of neonatal ovarian cysts.

Department of Surgery, University of North Carolina School of Medicine, Chapel Hill, North Carolina, and North Carolina Children's Hospital, Chapel Hill, North Carolina, WakeMed Hospital, Raleigh, North Carolina.

\*Paper from the 16<sup>th</sup> Annual IPEG Meeting.



**FIG. 1.** Laparoscopic-assisted transumbilical extracorporeal cystectomy technique with simple cyst delivery: (A) Cyst puncture (laparoscopic view). (B) Cyst decompression. (C) Cyst decompression (laparoscopic view).

There have been no published detailed comparison series examining outcomes in neonates treated by the same group of surgeons with these two different surgical techniques. Despite this, the laparoscopic approach appears to be rapidly becoming the favored approach of pediatric surgeons, per-

haps because of the potential advantages of improved cosmesis, shorter hospital stay and time to feeds, reduced pain, and faster return to normal activity (or parents to work).

After some initial frustration with laparoscopy in the removal of neonatal ovarian cysts, we developed a simplified single-incision laparoscopic-assisted transumbilical extracorporeal cystectomy (LATEC). The aim of this study was to review our experience with a consecutive series of neonatal ovarian cyst patients and to compare outcomes of the LATEC technique with those of our other surgically managed neonatal ovarian cyst patients.

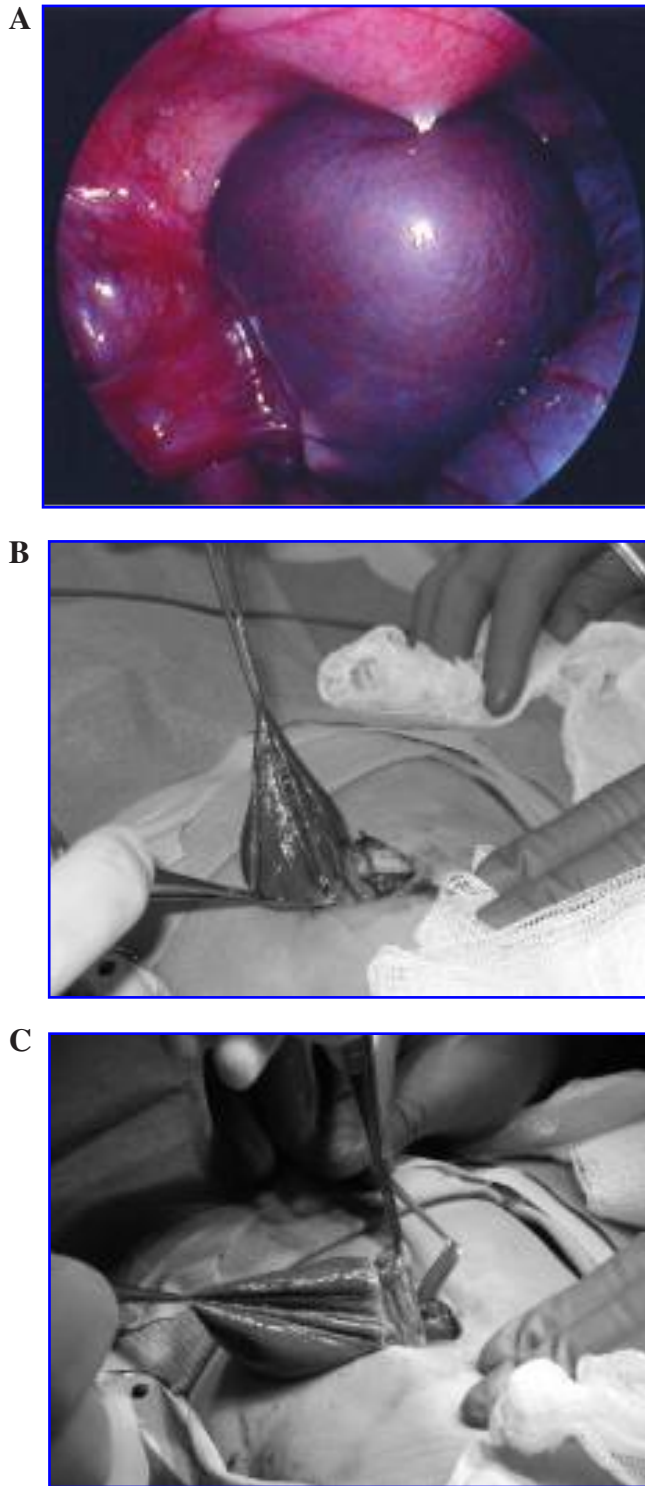
#### Materials and Methods

Clinical records of 21 consecutive newborns with neonatal ovarian cysts treated surgically by a single group of fellowship-trained pediatric surgeons at two tertiary medical centers between 1992 and 2006 were reviewed following institutional review board approval. Patients were identified from hospital databases by using diagnosis codes. Results were cross-matched with physicians' databases. One preterm patient, a twin of less than 32 weeks' gestation (birth weight, 1.79 kg), had a 27-day postoperative hospital stay due to severe respiratory distress syndrome and feeding difficulties. This was roughly 25 days longer than the mean 2-day hospital stay and not related to the presence of the ovarian cyst nor the surgical procedure. Therefore, this patient was considered an outlier and not included in this analysis.

All patients were less than 60 days old. Patients with neonatal ovarian cysts who did not undergo surgery were not included in this review. Patients with small cysts, less than 2–3 cm in diameter, are typically not referred to the pediatric surgery group at our institutions and, therefore, were also not included in this review.

The 20 patients were divided into three groups: open surgery (laparotomy), traditional laparoscopic surgery, and LATEC. All procedures were performed under general endotracheal anesthesia. Laparotomies were all transverse incisions (see below). Laparoscopic procedures involved the placement of at least two trocars (see below). For LATEC, one 5-mm umbilical trocar was inserted. Following insufflation with CO<sub>2</sub> to a pressure of 10-mm Hg, a 3.5-mm 30-degree laparoscope was introduced. Under laparoscopic guidance, transabdominal needle aspiration of the cyst was performed (see Figs. 1 and 2). The trocar was removed, the incision extended to a length of 15 mm, and the deflated cyst was exteriorized through the umbilicus for either cyst excision with ovarian preservation (simple cysts; see Fig. 1) or salpingo-oophorectomy (torsed/infarcted cysts; see Fig. 2).

Outcomes measured included time to beginning feedings, time to full feedings, postoperative narcotic use, length of hospital stay, and complications. Length of hospital stay was defined as the time from completion of surgery until final discharge. Cyst diameter was defined as the largest dimension without compression at postnatal ultrasound. Data were analyzed by using analysis of variance (ANOVA) and the Student's *t*-test for  $P < 0.05$ . Separate analyses were performed with grouping patients by the presence of torsion and cyst size rather than operative method. Follow-up ranged from 10 months to 14 years.



**FIG. 2.** Laparoscopic-assisted transumbilical extracorporeal cystectomy technique with torted cyst and oophorectomy. (A) Cyst puncture/aspiration (laparoscopic view). (B) Delivery of the ovary by an umbilical incision. (C) Oophorectomy.

## Results

Five patients were treated during the first half of the study (between January 1, 1992, and June 30, 1999), while the remaining 15 were operated on during the second half of the study (between July 1, 1999, and July 31, 2006). Mean age at

surgery was 11 days (range, 1–47). Average patient weight at surgery was 3.7 kg (range, 2.7–5.5). Nineteen of the 20 patients were diagnosed *in utero*, with a subsequent confirmation on postnatal ultrasound. One patient, followed by an outside perinatology group for bilateral moderate hydronephrosis, had a 4-cm complex, torted ovarian cyst overlooked during multiple *in utero* ultrasound studies. Indications for surgery included preoperative evidence of torsion (11 patients), large diameter with fear of future torsion (4 patients), and uncertain diagnosis (5 patients). There were no significant differences between the groups with respect to age at surgery, birth weight, or gestational age (see Table 1).

A transverse incision was used in all the open cases. Two of the incisions were supraumbilical and 6 were infraumbilical. Of the laparoscopic cases, a three-trocar technique was used for 2 patients, and two trocars were used in 3 patients. All patients in the LATEC group had one incision. Cyst size ranged from 2.9–6.7 cm (mean, 5.0). Eight cysts were left-sided, 11 were right-sided, and 1 patient had bilateral pathologic cysts. During surgery, it was discovered that 10 of the patients with unilateral pathologic cysts also had small cysts on the contralateral side. In 2 patients, the contralateral side was not visualized. Small cysts on the contralateral side were aspirated during surgery in 2 of the laparoscopic patients.

Fifteen cysts in 14 patients were complicated: 2 cysts were hemorrhagic (i.e., filled with clotted blood but not torted) and 13 cysts were torted (see Table 2). All torted cysts had caused infarction of the affected ovary and accompanying fallopian tube. One patient in the LATEC group had a bilateral torsion. Six of 8 patients in the open surgery group had complicated cysts, with 2 hemorrhagic and 4 torted. In the laparoscopic group, 4 of 5 patients had torted cysts, and in the LATEC group, 4 of 7 patients had torsion in 5 cysts. Of note, 5 of the 15 complex cysts (33%) were densely adherent to the small and/or large intestine. Three of the total 13 torted cysts (23%) were smaller than 4 cm in diameter (range, 2.9–3.5).

There were no significant differences found for operative times, times to beginning postoperative feedings, times to full feeds, lengths of stay, and postoperative narcotic use, when comparing all three groups by using ANOVA (see Table 3). Twelve of the 20 patients (60%) did not require any narcotics postoperatively. However, when traditional laparoscopy and LATEC were compared, there was a significant improvement in the LATEC cases in duration of surgery, postoperative length of stay, and time to full feeds. Mean duration of surgery of the LATEC cases was 45.6 minutes, compared to 83 minutes in the laparoscopy group. Mean time to full feeds was 20.5 hours versus 38.7 hours and a mean length of stay 30.9 hours, compared to 53.3 hours.

There were two major complications in the laparoscopy group. In 1 patient, a 3-mm trocar caused a bladder perforation. This was immediately recognized and repaired through a small incision. In another patient, a postoperative umbilical-wound infection required a readmission to the hospital for treatment with intravenous antibiotics and wound drainage. Neither of these two complications resulted in long-term patient morbidity.

## Discussion

The number of neonatal ovarian cyst patients requiring surgical treatment appears to be increasing. This increase

TABLE 1. PATIENT CHARACTERISTICS OF THE THREE TREATMENT GROUPS (LAPAROTOMY, LAPAROSCOPY, LATEC)

Characteristics	Laparotomy (n = 8)	Laparoscopy (n = 5)	LATEC (n = 7)
Surgical treatment during first half of study	5/8 (63%)	0/5	0/7
Gestational age (mean; range)	38.7 weeks (range, 36–41)	38.6 weeks (range, 36–40.4)	38.0 weeks (range, 35–40.7)
Age at surgery (mean; range)	16.3 days (range, 1–47)	4.8 days (range, 1–11)	9.6 days (range, 1–31)
Weight at surgery (mean; range)	3.8 kg (range, 2.7–5.5)	3.5 kg (range, 2.7–4.2)	3.7 kg (range, 3.0–4.3)
Indication for surgery			
Fear of future torsion due to size	1	1	2
Preoperative evidence of torsion	4	2	5
Uncertain diagnosis	3	2	0

LATEC, laparoscopic-assisted transumbilical extracorporeal cystectomy.

was especially evident in our series, with a tripling of the number of patients in the second half of our series, when compared to the first half. Our first neonatal laparoscopic case was performed in 1999, and since then, the majority of neonatal ovarian cyst operations done by our group have been with the use of laparoscopy. Transabdominal cyst aspiration has been advocated by some investigators, but suffers from limitations, including the inability to visualize a contralateral “normal” ovary, inability to lyse adhesions to adjacent intestinal loops, and possible damage to adjacent organs.<sup>13,14</sup>

Multiple different laparoscopic techniques have recently been reported for the surgical treatment of neonatal ovarian cysts. In 1995, van der Zee et al. described 2 cases of laparoscopic-assisted cyst mobilization with resection through 1-cm lower abdominal incisions.<sup>4</sup> In 1997, Bailez and Martinez Ferro described a technique utilizing either two or three trocars, with cyst extraction through a 10-mm umbilical trocar.<sup>15</sup> In 1999, Decker et al. described a three-trocar technique (with

all 5-mm trocars).<sup>16</sup> In 2002, Tseng et al. described a two-trocar technique, with extraction through a 5-mm infraumbilical incision.<sup>17</sup> Prasad and Chan, in 2007, described a technique quite similar to ours, with laparoscopic-assisted transumbilical cyst extraction.<sup>18</sup> However, a second port of 3 mm was utilized.

We chose to utilize a 3.5-mm 30-degree laparoscope, which is only 20 cm long and, therefore, quite easy to use. Although a 5-mm-diameter laparoscope could have been chosen (or even a 10-mm laparoscope, introduced through a 10-mm trocar) to take advantage of improved optics and enhanced imaging, these larger telescopes are usually much longer and thus may have been more difficult to navigate when operating on a small infant.

A significant potential impediment to the adoption of neonatal laparoscopy is the anticipated laparoscopic “learning curve,” in which improvements in patient outcomes typically cannot be demonstrated until the surgeon gains extensive experience with a new technique. This has

TABLE 2. OVARIAN CYSTS IN THE THREE TREATMENT GROUPS (LAPAROTOMY, LAPAROSCOPY, LATEC)

	Laparotomy (n = 8)	Laparoscopy (n = 5)	LATEC (n = 7)
Simple cysts	2	1	3
Complex cysts <sup>a</sup>	6 (2 hemorrhagic, 4 torsed)	4 (all torsed)	5 (1 bilateral, all torsed)
Maximal cyst diameter on postnatal ultrasound (mean; range)	5.3 cm (range, 3.5–6.7)	5.0 cm (range, 4.0–6.5)	4.5 cm (range, 2.9–5.3)

LATEC, laparoscopic-assisted transumbilical extracorporeal cystectomy.

<sup>a</sup>Complex cysts are defined as ovarian cysts that had either undergone spontaneous hemorrhage (into the cyst) or torsion, with infarction of the affected ovary and adnexal structures.



TABLE 3. OUTCOMES OF THREE TREATMENT GROUPS (LAPAROTOMY, LAPAROSCOPY, LATEC)

	Laparotomy (n = 8)	Laparoscopy (n = 5)	LATEC (n = 7)
Duration of surgery (min)	51.8 ± 17.1	83.0 ± 42.9	45.6 ± 14.1**
Time to feeds (hours)	19.9 ± 26.2	14.7 ± 14.2	9.4 ± 7.1
Time to full feeds (hours)	36.6 ± 27.8	38.7 ± 17.4	20.5 ± 12.0**
Postoperative length of stay (hours)	48.4 ± 33.8	53.3 ± 15.5	30.9 ± 11.5**
Postoperative morphine utilized (mg)	0.5 ± 0.07	0.6 ± 1.3	0.3 ± 0.05
Major complications (%)	0	40% (1 bladder perforation, 1 wound infection)	0
Ovarian preservation (simple cysts) (%)	50% (1 of 2)	100% (1 of 1)	100% (3 of 3)

Outcomes are defined as the means ± standard deviation.

LATEC, laparoscopic-assisted transumbilical extracorporeal cystectomy.

\*\* $P < 0.05$ , compared to laparoscopy.

been described for a number of advanced pediatric laparoscopic procedures, including fundoplication, appendectomy, splenectomy, and pyloromyotomy.<sup>19-22</sup> Laparoscopic-assisted procedures, such as LATEC, may allow the experienced pediatric surgeon to partially bypass this learning curve. LATEC is a relatively simple procedure that combines laparoscopy and traditional extracorporeal surgery.

One limitation of this study was that, despite being one of the largest reported series of neonatal ovarian cyst patients undergoing surgical treatment by a single group of pediatric surgeons, the sample size was small. Thus, statistical significance was difficult to demonstrate. In addition, increasing experience with neonatal ovarian cyst patients toward the end of the study (when many of the laparoscopic and LATEC procedures were performed) may have allowed the treating physicians to be more comfortable with the quicker advancement of enteral feedings and more rapid hospital discharge.

The surprising finding that 3 of the 13 torsed cysts had a diameter smaller than 4 cm challenges the traditional view that intervention is not necessary for simple cysts smaller than 4 cm. However, 2 of the 3 torsed cysts did have *in utero* measurements, suggesting the risk for subsequent torsion. The first of these patients, with a cyst diameter of 3.5 cm measured postnatally on day 2 of life, had previous *in utero* measurements of 4.0 cm at 31 weeks and 3.0 cm at 38 weeks prior to delivery at 38.5 weeks. The second of these patients, also with a 3.5-cm cyst measured postnatally on day 1 of life, had an *in utero* measurement of 4.0 cm. The third of these patients, with a 2.9-cm cyst, had an *in utero* measurement of 2.5 cm at 37 weeks' gestation. Earlier referral to a pediatric surgeon may be warranted in the management of smaller cysts, particularly given the low morbidity of this technique and the serious complications that have been reported to result from ovarian torsion.<sup>5-9</sup> In addition, patients with bilateral cysts have the potential for bilateral torsion and the subsequent loss of all ovarian tissue.<sup>10</sup>

## Conclusions

This series was the first to compare traditional "open" surgery to laparoscopic methods for the surgical treatment of neonatal ovarian cysts. It appears that new, simpler laparoscopic techniques have significant advantages over other approaches. LATEC is a procedure that appears to have the advantages of laparoscopy, such as excellent visualization of the contralateral ovary, rapid postoperative recovery, and excellent cosmesis, with only a single incision. Further, this procedure may offer a better chance for ovarian preservation and the management of complex cysts.

## Acknowledgment

Funded, in part, by a National Institute for Diabetes and Digestive and Kidney Diseases Short Term Research Training grant.

## References

1. Valenti C, Kassner EG, Yermakov V. Antenatal diagnosis of a fetal ovarian cyst. *Am J Obstet Gynecol* 1975;15:216-219.
2. Nussbaum AR, Sanders RC, Hartman DS, Dudgeon DL, Parmley TH. Neonatal ovarian cysts: Sonographic-pathologic correlation. *Radiology* 1988;168:817-821.
3. Brandt ML, Luks FI, Filiatrault D, Garel L, Desjardins JG, Youssef S. Surgical indications in antenatally diagnosed ovarian cysts. *J Pediatr Surg* 1991;26:276-282.
4. van der Zee DC, van Seumeren IG, Bax KM, Rovekamp MH, ter Gunne AJ. Laparoscopic approach to surgical management of ovarian cysts in the newborn. *J Pediatr Surg* 1995;30:42-43.
5. McKeever PA, Andrews H. Fetal ovarian cysts: A report of five cases. *J Pediatr Surg* 1988;23:354-355.
6. Bagolan P, Rivosecchi M, Giorlandino C, Bilancioni E, Nahom A, Zaccara A, Trucchi A, Ferro F. Prenatal diagnosis and clinical outcome of ovarian cysts. *J Pediatr Surg* 1992;27:879-881.

7. Bagolan P, Giolandino C, Nahom A, Bilancioni E, Trucchi A, Gatti C, Aleandri V, Spina V. The management of fetal ovarian cysts. *J Pediatr Surg* 2002;37:25–30.
8. Karmazyn B, Steinberg R, Ziv N, Zer M, Horev G. Colonic stricture secondary to torsion of an ovarian cyst. *Pediatr Radiol* 2002;32:25–27.
9. DeSa DJ. Follicular ovarian cysts in stillbirths and neonates. *Arch Dis Child* 1975;50:45–50.
10. Corbett HJ, Lamont GA. Bilateral ovarian autoamputation in an infant. *J Pediatr Surg* 2002;37:1359–1360.
11. Ferro F, Iacobelli BD, Zaccara A, Spagnoli A, Trucchi A, Bagolan P. Exteriorization-aspiration minilaparotomy for treatment of neonatal ovarian cysts. *J Pediatr Adolesc Gynecol* 2002;15:205–207.
12. Esposito C, Garipoli V, Di Matteo G, De Pasquale M. Laparoscopic management of ovarian cysts in newborns. *Surg Endosc* 1998;12:1152–1154.
13. Sapin E, Barga F, Lewin F, Baron JM, Adamsbaum C, Barbet JP, Helardot PG. Management of ovarian cyst detected by prenatal ultrasounds. *Eur J Pediatr Surg* 1994;4:137–140.
14. Sakala EP, Leon ZA, Rouse GA. Management of antenatally diagnosed fetal ovarian cysts. *Obstet Gynecol Surg* 1991;46:407–414.
15. Bailez M, Martinez Ferro M. Endosurgical postnatal approach to fetal ovarian cysts. *Pediatr Endosurg Innovat Tech* 1997;1:111–116.
16. Decker PA, Chammas J, Sato TT. Laparoscopic diagnosis and management of ovarian torsion in the newborn. *JSL* 1993;3:141–143.
17. Tseng D, Curran TJ, Silen ML. Minimally invasive management of the prenatally torsed ovarian cyst. *J Pediatr Surg* 2002;37:1467–1469.
18. Prasad S, Chan H. Laparoscopic-assisted transumbilical ovarian cystectomy in a neonate. *JSL* 2007;11:138–141.
19. Meehan JJ, Georgeson KE. The learning curve associated with laparoscopic antireflux surgery in infants and children. *J Pediatr Surg* 1997;32:426–429.
20. Cusick RA, Waldhausen JH. The learning curve associated with pediatric laparoscopic splenectomy. *Am J Surg* 2001;181:393–397.
21. York D, Smith A, von Allmen D, Phillips JD. Laparoscopic appendectomy in children after the learning curve. *JSL* 2006;10:447–452.
22. Adibe OO, Nichol PF, Flake AW, Mattei P. Comparisons of outcomes after laparoscopic and open pyloromyotomy at a high-volume pediatric teaching hospital. *J Pediatr Surg* 2006;41:1676–1678.

Address reprint requests to:

*J. Duncan Phillips, MD*

*Department of Surgery*

*3010 Old Clinic Building, CB #7223*

*Chapel Hill, NC 27599*

*E-mail: Duncan\_Phillips@med.unc.edu*